

**SAFETY AND FERTILITY ENHANCING ROLE OF *MORINGA OLEIFERA* LEAVES AQUEOUS EXTRACT IN NEW ZEALAND RABBIT BUCKS**

Walaa H. Khalifa¹, Faten M. Ibrahim², Aida I. El makawy*³, Hafiza A. Sharaf⁴, Wagdy K. B. Khalil³, Nagwa A. Maghraby¹

¹Animal Production Dept., ²Medicinal and Aromatic Plants Research Dept., ³Cell Biology Dept., ⁴Pathology Dept., National Research Centre, 33 El Bohouth St. - Dokki- Giza-Egypt-P.O.12622.

*Corresponding author e-mail: aelmakawy@yahoo.com

Received on: 30-08-2015; Revised on: 10-12-2015; Accepted on: 18-01-2016

ABSTRACT

The objective of this study is to evaluate the safety of *Moringa oleifer* leaves aqueous extract and its role on fertility of New Zealand rabbit bucks. Two doses of *Moringa oleifer* leaves extract (200 and 400 mg/kg/day) were administrated to rabbit bucks via gavage for 21 days. Sildenafil citrate at dosage of 5mg/kg was used as reference drug. Liver, kidney and lipid profile functions were evaluated as safety profile agent of *Moringa oleifer* leaves extract. Fertility parameters such as body weight, testosterone and thyroid hormones levels, physical characteristics of epididymal sperm, expression of reproductive genes and histopathological changes in rabbit bucks were investigated to evaluate the role of *Moringa oleifer* on enhancing the fertility of rabbit bucks. Results revealed that *Moringa oleifer* did not cause any toxic effect. In addition, the results illustrated that the effect of *Moringa oleifer* in enhancing male fertility clearly manifested in increase the level of testosterone, thyroid activity, sperm (motility, viability, membrane integrity), up regulation of reproductive gene expression. In addition, *Moringa oleifer* showed improvement in the histological structure of rabbit bucks testicular tissue. Based on these findings, we can conclude that the aqueous extract of *Moringa oleifer* leaves is safe and has the potential to enhancing the rabbit bucks fertility.

Keywords: *Moringa oleifer*, Rabbit bucks, fertility hormones, reproductive gene expression, histopathological investigation

INTRODUCTION

In Africa a wide variety of plants are of great medicinal and nutritional importance. Plants have been used for thousands of years to flavor and conserve food, to treat health disorders and to prevent diseases including epidemics.^[1] Herbal therapy can alleviate male infertility, irrespective of the etiology of such diseases.^[2] A large number of plants have been tested for the possible fertility regulatory properties.^[3-6] Some medicinal plants are extensively used as aphrodisiac to relieve sexual dysfunction or as fertility enhancing agents. They provide a boost of nutritional value thereby improving sexual performance and libido.^[7,8] *Moringa oleifer* is the

most widely distributed species of Moringaceae family, having an impressive range of medicinal uses with high nutritional value throughout the world. Moringa tree was utilized by the ancient Romans, Greeks and Egyptians and all parts are edible and have long been consumed by humans, and their antioxidant concentrations warrant the plant's image as a healthy food source.^[9] Recently, there has been interest in the utilization of Moringa (*Moringa oleifer*) as a protein source for livestock. *Moringa oleifer* leaves have quality attributes that make them potential replacement for soya bean in diets of rabbit.^[10]

Moringa oleifer plant family is rich in compounds containing the simple sugar, rhamnose,

and it is rich in a unique group of compounds called glucosinolates and isothiocyanates.^[11] It is also has become an outstanding indigenous source of highly digestible protein, calcium (Ca), iron (Fe), amino acids and antioxidants. These nutritional characteristics of the plant may be, potentially beneficial to the developing regions of the world where undernourishment is a major concern showed by Mori et al.^[12]; Ashfaq et al.^[13] and Tesfay et al.^[14]

Moringa oleifera contains specific plant pigments with demonstrated powerful antioxidative ability such as vitamins C, E, A, caffeoylquinic acids, carotenoids - lutein, alpha-carotene and beta-carotene, kaempferol, quercetin, rutin.^[15] Studies on *Moringa oleifera* showed that the leaves are rich in energy and vitamins.^[16, 17]

In addition, it has been demonstrated that *M. oleifera* leaf extracts inhibit 6- β -hydroxylation of testosterone; therefore, the sexual enhancing potential of this plant has gained attention.^[18] Moreover, it used to enhance male sexual functions including libido, improve sperm quality and anti-erectile dysfunction.^[19]

The management options available for the treatment of infertility in males include the use of drugs and a variety of surgical procedures.^[20] Thus, having a balanced level of hormone is essential to proper fertility in the reproductive health of both men and women. On this accounts, many plant-derived chemicals that influence endocrine activities in both humans and animals have received a great deal of attention due to their possible benefits as well as adverse effects.^[21] Additionally, some of these plants known to possess anti-fertility effect through their action on the hypothalamic-pituitary-gonadal axis or direct hormonal effects on reproductive organs. In view of the consumption of *Moringa oleifera* leaves extracts for the maintenance of health and well-being and for the enhancement of male fertility. This work is a study aimed at evaluating the safety of *Moringa oleifera* leaves aqueous extract and its role on fertility of New Zealand rabbit bucks. The study was conducted by measuring of testosterone, T3, T4 and FSH serum levels. Liver, kidney and lipid profile functions in rabbits bucks were evaluated as safety profile agent on *Moringa oleifera* leaves extract. Fertility parameters such as body weight, Physical characteristics of epididymal sperm and expression of Aromatase, luteinizing hormone, and follicle-stimulating hormone genes were studied. In addition, testes and liver of rabbit bucks histopathological structures were investigated.

MATERIALS AND METHODS

Identification and Extraction of Plant Material:

Moringa oleifera leaves were collected from the farm of Egyptian Scientific Society of Moringa. The plant was identified by Prof. Dr. Aboelfetoh Mohammed Abdelalla, National Research Center; Giza, Egypt. The collected leaves was air-dried, powdered and kept for extraction. The resulting powder (500 g) was extracted with 2L of distilled water and left to stand for 48 hours at room temperature. The extract was filtered with Whatman No. 1 filter paper. The crude aqueous extract was concentrated using rotary evaporator under reduced pressure at 45°C then the concentrated extracts were lyophilized and kept at -20°C.

Animals and Dosing:

The experiments were carried out using 20 sexually mature New Zealand white rabbit's bucks weighing 2.40 ± 0.08 kg. The animals were acquired from the Rabbit Research Unit of Agriculture Experimental Station, Faculty of Agriculture, Cairo University, and housed in polyethylene boxes in a climate-controlled environment ($25^\circ \pm 4^\circ\text{C}$, $55 \pm 5\%$ humidity) with a 12-h light/dark cycle. They were fed on commercial food pellets and drinking water *ad libitum*. The rabbits were divided into 4 groups of 5 rabbits each. The first group received drinking distilled water *ad libitum* and served as negative control. The second group were received a dosage of 5mg/kg of sildenafil citrate (Viagra tablets, German Remedies) and used as reference group. The third and fourth groups were received aqueous extract of *Moringa oleifera* leaf at the dosage of 200 and 400 mg/kg. A calculated dose of the extract according to the initial body weight of the rabbits was administered orally to each rabbit at 8 a.m. daily for 21 days respectively. Body weights of the rabbits were measured weekly. This study was carried out following approval from the Ethical Committee on the Care and Use of Experimental Animals for Research. At the end of the experimental period, the rabbits were starved for 12 h and blood samples were collected then animals were sacrificed under ether anaesthetized. For biochemical evaluations, blood samples were collected from the marginal ear vein of the rabbits and received into clean dry centrifuge tube and left to clot at room temperature, then centrifuged for 10 minutes at 3000 r.p.m to separate serum. Serum was carefully separated into dry clean Wassermann tubes, using a Pasteur pipette and kept frozen at (-20°C) until estimation of some biochemical parameters. For gene expression blood samples were stored immediately in freezer at -4°C.

Hormonal assessment:

Testosterone: The level of testosterone was measured in serum by ELISA testosterone, standard kits (Biocheck, Inc. Foster City CA, USA). The procedure described in the hormone assay kits was used according to the principle highlighted by Tietz,^[22]

Thyroid hormones: Estimation of serum T3, T4, TSH was done by chemiluminescence immunoassay method according to Demers and Spencer,^[23]

Biochemical assessment: Uric acid was determined in the serum according to the method described by Fossati et al.^[24] Urea nitrogen was determined according to Patton & Crouch.^[25] Creatinine was determined according to Bartels et al.^[26] Total cholesterol and HDL-cholesterol were determined by the method of Stein.^[27] Cholesterol- LDL was calculated according to Friedewald *et al.*^[28] Triglyceride was measured in serum by the method of Wahelfed^[29] Total lipid was measured in serum by the method of Zollner and Kirsch.^[30] Determination of aspartate and alanine aminotransferases (AST and ALT) enzyme activities: AST and ALT were measured in serum by the method of Reitman and Frankel.^[31] Total protein was determined in serum according to the method of Bradford.^[32] All kits were purchased from Biodiagnostic, Egypt.

Semen collection and physical properties evaluation: After 8 wk of adaptation to experimental treatments, semen collection and evaluation was done on bucks of all experimental groups. Semen collected twice a week for five consecutive weeks by the same handler in all groups according to IRRG Guidelines standard procedure.^[33]

Sperm motility: Sperm motility was estimated by placing a drop of the suspension on a clean glass slide under the cover slip. Motile and immotile spermatozoa were counted under a microscope with phase contrast optics (100×) according to Seleem.^[34]

Sperm Viability: Sperm viability was assessed by nigrosin/eosin (N/E) staining procedure according to Cecil.^[35] About 500 spermatozoa in each smear were counted by microscopy (magnification 100 xs) and the proportion of viable spermatozoa was calculated on the total number of cells.

Sperm plasma membrane integrity: Sperm membrane integrity was determined in semen samples in a 1:10 dilution of hypoosmotic swelling test (HOST) solution according to Moce et al.^[36] and

incubated at 37°C for 30 min. After incubation, a 5µl semen sample drop was examined under a phase-contrast microscope 400-x magnification. The grades and percentages of spermatozoa with swollen heads and coiled tails were estimated. The swollen spermatozoa characterized by coiling of the tail were considered to have an intact plasma membrane.

Sperm Morphological Abnormalities: The nigrosin-eosin stained semen smears as used in live sperm counts were also utilized in determining the percentage of morphological abnormal spermatozoa, while the smear was examined with bright field microscopy at 400 -x magnification [34].

Histopathological Assay: For histopathological studies, testes and Liver tissues were cut and fixed in 10% formalin saline. After the fixation, the tissues were washed and processed by standard histology procedures and embedded in paraffin. Tissue sections were stained with haematoxylin and eosin (H&E). The stained slides were examined under a light microscope.

Expression of Aromatase, luteinizing hormone (LH), and follicle-stimulating hormone (FSH) genes

Total RNA Isolation: Total RNA from peripheral blood of rabbit bucks was isolated using the standard TRIzol® Reagent extraction method (cat#15596-026, Invitrogen, Germany). Total RNA was pretreated using RQ1 RNase-free DNase (Invitrogen, Germany) to remove any possible genomic DNA residues following the manufacturer's protocol.

Reverse transcription (RT) reaction: The complete Poly (A)⁺ RNA was reverse transcribed into cDNA in a total volume of 20 µl using RevertAid™ First Strand cDNA Synthesis Kit (MBI Fermentas, Germany). The composition of reaction mixture, termed as master mix (MM) was consisted of 50 mM MgCl₂, 5x reverse transcription (RT) buffer (50 mM KCl; 10 mM Tris-HCl; pH 8.3; 10 mM of each dNTP (Amersham, Brunswick, Germany), 50 µM oligo-dT primer, 20 U ribonuclease inhibitor (50 kDa recombinant enzyme to inhibit RNase activity) and 50 U M- MuLV reverse transcriptase. The RT reaction was carried out at 25 °C for 10 min, followed by 1 h at 42 °C, and the reaction was stopped with denaturation step at 99 °C for 5 min. Afterwards the reaction tubes containing RT preparations were flash-cooled in an ice chamber until being used for DNA amplification through quantitative real time-polymerase chain reaction (qRT-PCR). Quantitative real time-polymerase chain reaction (qRT-PCR) were set up in 25 µL reaction

mixtures containing 12.5 μL $1\times$ SYBR® Premix Ex Taq™ (TaKaRa, Biotech. Co. Ltd., Germany), 0.5 μL 0.2 μM sense primers, 0.5 μL 0.2 μM antisense primer, 6.5 μL distilled water, and 5 μL of cDNA template. The PCR cycling steps were one cycle of 95.0°C for 3 min, 40 cycles of 95.0°C for 15 s; 55.0°C for 30 s; and 72.0°C for 30 s. The final step consisted of 71 cycles which started at 60.0°C and then increased about 0.5°C every 10 sec up to 95.0°C. The quantitative values of RT-PCR (qRT-PCR) of Aromatase (Cyp19-F: 5'-ATA CCA GGT CCT GGC TAC TG-3', Cyp19-R: 5'-TTG TTG TTA AAT ATG ATG CC-3', [37], LH (LH -F: 5'-TCT CAC CACCAC CGT CTG TA-3', LH-R: 5'-TGC AGT CGC TGT AGT CCA TC-3', [37] and FSH (FSH-F: 5'-GGG CCA GGA ACT GTG AAA TA-3', FSH-R: 5'-TCT CAG AAC TGC CGA GGT TT-3', [37] genes were normalized on the bases of β -actin (β -actin-F: 5'-TTG CCG ACA GGA TGC AGA A-3', β -actin-R: 5'-GCC GAT CCA CAC GGA GTA CT-3', [37] expression. At the end of each qRT-PCR a melting curve analysis was performed at 95.0 °C to check the quality of the used primers. The amplification efficiency (Ef) was calculated from the slope of the standard curve using the formulae of Bio-Rad Laboratories Inc. Real-Time PCR Applications Guide: $Ef = 10^{-1/\text{slope}}$ Efficiency (%) = $(Ef - 1) \times 100$. The relative quantification of the target to the reference was determined by using the ΔCT method if E for the target (Cyp19, LH and FSH) and the reference primers (β -Actin) are the same. $\text{Ratio}_{(\text{reference}/\text{target gene})} = Ef^{\text{CT}(\text{reference}) - \text{CT}(\text{target})}$

Statistical analysis: Data of hormones, biochemical and semen physical characteristics were analyzed using one-way analysis of variance (ANOVA) tests for comparisons among means. Duncan's multiple range tests were used to locate points of significant differences between groups. Gene expression data were analyzed using the general linear models (GLM) procedure of statistical analysis system [38] followed by Scheffé-test to assess significant differences between groups. The values are expressed as mean \pm SD. All statements of significance were based on probability of $P \leq 0.05$.

RESULTS

Body weight: The data of Table (1) illustrate that *Moringa oleifera* leaves extract at the dose of 200 and 400mg/kg showed no significant differences in the body weights of rabbit bucks through two weeks of the start time of the experiment as compared to control and sildenafil citrate groups. While, through the next two weeks there was significant decrease ($p \leq 0.05$) in the body weights of high dose *Moringa oleifera* extract administered bucks than control.

Whereas, there was no significant difference between *Moringa oleifera* high dose and sildenafil citrate group.

Hormonal Data: The results show that the *Moringa oleifera* leaf aqueous extract oral administration at the dose of 200 and 400mg/kg for 21 days to male rabbits increased the thyroid activity as tabulated in Table 2. *Moringa oleifera* significantly increased the level of T3 and T4 as compared to those of control and sildenafil citrate groups. While, the thyroxine-stimulating hormone (TSH) level of *Moringa oleifera* treated animals was none significantly increased over control animals. With regard to the data of the level of serum testosterone, *Moringa oleifera* significantly ($p \leq 0.05$) increased the level of testosterone when compared to the control as shown in Table 2. Meanwhile, the serum testosterone levels of *Moringa oleifera* two doses were significantly increased than those of Sildenafil citrate group.

Biochemical Data: Data illustrated in Table (3) show that there was no significant difference in the protein content of *Moringa oleifera* leaves extract treated and control rabbit bucks. *Moringa oleifera* leaves extract at dose 200mg/kg was significantly increased the level of Glutamic –oxalacetic Transaminase ($p \leq 0.05$) as compared to control. However, the dose of 400mg/kg decreased significantly ($p \leq 0.05$) the level of Glutamic –oxalacetic Transaminase than control. Nevertheless, *Moringa oleifera* leaves extract two doses did not affect the level of Glutamic pyruvic Transaminase significantly. In addition, there were no significant differences in the levels of Creatinine, urea and uric acid of *Moringa oleifera* leaves extract administered animals and those of control. As regarding to Sildenafil citrate, results revealed that it significantly increased ($p \leq 0.05$) the levels of Glutamic –oxalacetic Transaminase, Glutamic pyruvic Transaminase and urea in rabbit bucks as shown in Table 3.

Data illustrated in Table (4) show the effect of oral administration of *Moringa oleifera* leaves aqueous extract at doses of 200mg/kg and 400mg/kg and Sildenafil citrate 5mg/kg for 21 days on total cholesterol, high-density lipoprotein (HDL) cholesterol, low-density lipoprotein (LDL) cholesterol, triglyceride and total lipid. Results revealed that the *Moringa oleifera* leaf aqueous extract at two doses significantly decreased ($p \leq 0.05$) the levels of total cholesterol, LDL and total lipids. Meanwhile, the low dose of *Moringa oleifera* leaf aqueous extract none significantly decreased the levels of HDL and triglycerides than control. Whereas, the high dose showed significant ($p \leq 0.05$) increase in HDL and

decrease in triglycerides as compared to control. While, Sildenafil citrate treatment surpassed the levels of total cholesterol, LDL and triglyceride with significant differences ($p \leq 0.05$) as compare to control. Meanwhile it was significantly increased the level of HDL and none significantly decrease the level of total lipid.

Sperm Physical Properties: The result of sperm analysis revealed that the administration of *Moringa oleifera* leaves aqueous extract at dose of 200 mg/kg for 21 days none significantly increased the sperm motility and viability as compared to control as in Figure 1&2. While, the sperm membrane integrity was significantly decreased ($p \leq 0.05$) than control but it increased significantly as compared to sildenafil citrate as in Figure 3. Meanwhile, sildenafil citrate significantly decreased ($p \leq 0.05$) the percentage of motility, viability and membrane integrity than control as show in Figure 1-3. Meanwhile, *Moringa oleifera* aqueous extract low dose and sildenafil citrate show significant increase in the frequency of sperm morphological abnormalities than control as in Figure 4. As regards to High dose (400mg/kg) sperm analysis data show that moringa extract increase the percentage of sperm motility, viability and membrane integrity than control and sildenafil citrate as show in Figure 1-3. Whereas, it decreased significantly the sperm morphological abnormalities than control and sildenafil citrate animals as show in Figure 4.

Histopathological results: Microscopic examination of the testis of the control rabbit ducks showed normal histological structure of testicular tissue as show in Figure (5A), and regular arrangement of the seminiferous tubules with normal germinal epithelium as well as developing and mature spermatozoa. The lumen was seen packed with spermatids and spermatozoa. Whereas, testis of sildenafil citrate (Viagra, 5 mg/kg, b.w) treated bucks showed tubular and interstitial histological alterations as seen in Figure (5 B), sever destruction of the seminiferous tubules with large necrotic areas and degenerative cells. The spermatozoa are completely absent in most of the seminiferous tubules. The Sertoli cells showing more damage as well as the spermatogonia (A and B types) in cytoplasmic vacuolation, thinking in interstitial area and hyperplasia in Leydig cell number. *Moringa oleifera* leaves extract administration led to improvement in the histological structure of rabbit bucks testicular tissue than normal control animals. Rabbits treated with 200mg/kg for 21 day showed seminiferous tubules, spermatogonia, spermatocytes, spermatids as well as Sertoli cells seem similar to control animals as show in Figure 5 C. No much differences can be observed between sections of *Moringa oleifera*

leaves extracts low (200 mg/kg) and high (400mg/kg) doses treated bucks as show in Figure (5 C & D) respectively. Moreover, (400mg/kg) doses of *Moringa Oleifera* leaves extract administrated bucks revealed hyperactivity of germinal epithelium cells, increases in numbers of cells at all stages of spermatogenesis, the density of spermatids and spermatozoa were more prominent in lumen of seminiferous tubule and the interstitial areas are wider with health Leydig cells than that of control.

As regarding to liver microscopic examination, control section of rabbit bucks showed normal structure of hepatic lobules formed of radially arranged cords of liver cells from central vein to periphery of lobule separated by blood sinusoids (Figure 6 A). Rabbits treated with sildenafil citrate (Viagra, 5 mg/kg) for 21 days revealed sever damaged of liver tissue, vacuolar and fatty degeneration of hepatic cells, hemorrhage, congestion of central vein and blood sinusoids, (Figure 6 B). Animals treatment with *Moringa oleifera* leaf extract showed no considerable pathological changes in liver tissues. The dose 200mg/kg for 21 day exhibited moderate dilation of blood sinusoids and hypertrophied of kupffer cells, while hepatocytes tissues almost normal (Figure 6 C). Meanwhile, the section of liver treated with 400mg/kg for 21 day showed the structure of liver tissue nearly as normal except dilation of central vein and blood sinusoids which appeared field with blood (Figure 6 D). No much differences can be observed between sections of low (Figure 6 C) and high doses (Figure 6 D) of *Moringa oleifera* leaves extracts treated rabbits.

Expression analysis of CYP19, LH and FSH genes: The effect of different doses of *Moringa oleifera* leaves aqueous extract (200 and 400 mg/kg b.w) and sildenafil citrate (Viagra, 5 mg/kg, b.w) on the expression of CYP19 and LH as well as FSH genes in blood cells of rabbit bucks are summarized in Figures 7-9. The expression levels of CYP19, LH and FSH genes were increased insignificantly with low dose of *Moringa oleifera* extract compared with control group (Figs. 7-9). Moreover, treatment of rabbit bucks with high dose of *Moringa oleifera* extract increased significantly ($P \leq 0.05$) the levels of CYP19, LH and FSH genes compared with control group (Figs. 7-9). Furthermore, supplementation of rabbit bucks with sildenafil citrate (Viagra) for one hour prior to the commencement of the experiment increased significantly ($P \leq 0.05$) the levels of CYP19, LH and FSH genes compared with control group (Figs. 7-9), however, the expression levels of these genes were lower compared with high dose of *Moringa oleifera* extract. On the other hand, administration of rabbit bucks with sildenafil citrate

(Viagra) for 21 days increased significantly ($P \leq 0.01$) the levels of CYP19, LH and FSH genes compared with control group (Figs. 7-9), however, the expression levels of these genes were at the highest levels compared with all doses of *Moringa oleifera* extract.

DISCUSSION

In the present study, the body weight of the *Moringa oleifera* treated animals remained unchanged at the first two weeks of the experiment but at the third week, the high dose of Moringa induced significant decrease in the animal body weights. This result was in agree with [39] concluded that consumption of *M. oleifera* leaves at doses of up to 2000 mg/kg were safe. A dose-dependent decrease in body weights of the rats occurred over the 21 days of the study. Cajuday and Pocsidio [40] found that the body weight of the *M. oleifera* leaves extract treated animals for 21 days remained unchanged, which showed that the doses selected did not exert any harmful effect and the metabolic processes of the treated animals were normal. Stohs and Hartman [41] confirmed that no adverse effects were reported in a human study conducted with whole leaf powder at up to a single dose of 50 g or in a study using 8 g per day dose for 40 days. The effect of *Moringa oleifera* in enhancing male fertility clearly manifested in the treated groups compared with the control. The results illustrated that the *Moringa oleifera* significantly increased the level of testosterone and thyroid activity (T3, T4). Testosterone supplementation has previously been shown to improve sexual function and libido. [42] Amini and Kamkar [43] suggested that the plant extracts might have a role in testosterone secretion allowing better availability of hormone to gonads. *Moringa oleifera* leaf extracts inhibit β hydroxylation of testosterone. It produces androgenic effect by enhancing sexual drive through increased serum and testicular testosterone levels, increased blood flow to the male reproductive organs and stimulating the nervous system to enhance sexual desires. [18] The result of the present work was in accordance with [44] they reported that the aqueous leaf extract of *Moringa oleifera* up to dose of 500mg/kg showed increase in thyroid activity of male albino rats and the TSH level correlated well inversely with T3 and T4 levels. Thyroid hormones play important role on growth and development of the body and regulate metabolism. [45] Therefore, with an increase in thyroid activity, marked changes in thyroid hormone production, metabolism and action occur. This may result in an enhancement in spermatogenesis and male fertility. [46] In addition, data of the present study showed that *Moringa oleifera* significantly increased the sperm physical

characteristics (motility, viability and membrane integrity) of rabbit bucks. It is apparent that *M. oleifera* can enhance sexual activity in mice and have an opportunity to exert its effect depending on certain conditions of male animals. [47] The antioxidants present in the leaves of the plant, acting in concert with the antioxidant system present in the epididymis further preserved and enhanced the process of spermatogenesis. D'cruz and Mathur [48] proved that the sperm cytoplasm contained very low concentrations of scavenging enzymes therefore an increase in the antioxidant enzyme levels by Moringa treatment could favor the reproductive process. Abu et al. [49] results showed that *Moringa oleifera* leaf meal did not significantly influence sperm motility and concentration of the rabbits. However, a positive correlation was observed between inclusion levels of *Moringa oleifera* leaf meal and sperm concentration ($r=0.44$), suggesting *Moringa oleifera* leaf meal might have increased the sperm concentration of the rabbits. Although the sperm concentration of control rabbits is lower relative to those fed *Moringa oleifera* leaf meal, there was no corresponding increase when the rabbits were fed increasing inclusion levels of the meal. It is conceivable that the increase in sperm concentration might lead to higher fertility, which supported by the findings of Oyeyemi et al. [50] Our finding was also corroborates with the finding of Zade et al. [51] reported that administration of aqueous seed extract of *M. oleifera* has positive effect on spermatogenesis in rats. These results may be attributing to presence of flavonoids that can ameliorate oxidative stress-related testicular impairments in animal tissues. [52] In addition, Shukla and Khanuja [53] reported that steroid and saponin constituents found in many plants possess fertility potentiating properties, and they are useful in the treatment of impotence. The saponins may boost the level of testosterone in the body as well as trigger libido-enhancing effect. [54] The presence of flavonoids in the *M. oleifera* extract which has been implicated to have a role in altering androgen levels [55] may also be responsible for the enhanced male sexual behavior. The data recorded on lipid profile in control and *M. oleifera* treated rabbit bucks revealed that the *Moringa oleifera* significantly lowering the levels of total cholesterol, LDL, triglycerides and the total lipids levels where as HDL was elevated. These results were in agreement with Mehta et al. [56] in their study on rabbits and Tabassum et al. [44] on male albino rats. The relationship between serum lipid parameters and thyroid hormones confirm the presence of an inverse relationship between thyroxin serum levels and cholesterol [57]. Moreover, most of the serum biochemical parameters as total protein, GOT, GPT, Creatinin, uric acid and urea of *Moringa*

oleifera treated animals exhibited non-significant changes. These results were in accordance with [58] results of their safety evaluation studies on leaf and flower of Moringa. In addition, Ahemen et al. [59] concluded that inclusion of *Moringa oleifera* leaf meal in the diets of weaned rabbits up to 15% has no adverse effect on blood profile of rabbits. The histoarchitectural evidence was the clear indication of confirming the spermatogenic efficacy of extracts of *M. oleifera* leaves in rabbit bucks. Zade et al. [48] reported that the numbers of mature leydig cells as well as number of spermatocytes and spermatids were significantly increased in *Moringa* treated testes. Increment in the volume of cells and nucleus was strongly suggestive of steroid synthesis under the direct or indirect influence of the plant extract. This suggests a supposed role of testosterone in increasing the vascularisation of testicular tissue. Increased spermatogenesis was evident by high number of spermatozoa in seminiferous tubules and increase in spermatogenic elements as compared to control. Akudu et al. [60] histopathological results revealed that there was non-distortion of testicular cells observed in *Moringa oleifera* leaf extract treated groups. Isitua and Ibeh [61] illustrated that the effect of *M. oleifera* leaves extracts on selected enzymes showed an enhancement in the activities of alkaline phosphatase, acid phosphatase, aspartate transaminase and alanine transaminase. This finding suggests that the plants leaves may have the capacity to enhance the proper functioning of the liver, prostate gland, and hepatobiliary activity. This is in agreement with Saalu et al. [62] that have shown the antioxidative properties of *Moringa oleifera* and its ability to elevate a variety of antioxidant enzymes and testicular biomarkers. This could provide an interpretation for the finding in our study why the *Moringa oleifera* leaf extracts showed an enhanced sperm parameters, hormonal levels and testis histopathological morphology. Reproduction regulation by the brain is through the brain-pituitary-gonad (BPG) axis, which controls the pituitary gonadotropin hormone including the gonadotropin-releasing hormone (GnRH), follicle-stimulating

hormone (FSH) and luteinizing hormone (LH). The FSH and LH are the hormones, which induce the synthesis of the sex hormones such as 17 β -estradiol (E2) and testosterone, which control ovulation and spermatogenesis development. The E2 operates on a positive and negative feedback roles on the gonadotropin or its upstream hormone synthesis and secretion, through direct interaction with estrogen. [63] The current results revealed that *M. oleifera* extracts up regulated the expression of fertility genes (CYP19, LH and FSH). These findings are in line with study of Gopi and Varma [64] they reported that *Moringa Oleifera* leaf extract has the potential to fight against male infertility disorders. The leaf extract found to increase the sperm count, sperm concentration, mounting frequency and intromission number, increased testosterone level, increased dopamine content that all contribute to proper erection. On the other hand, data of the present study revealed that sildenafil citrate caused alteration in the sperm viability and membrane integrity, increased sperm abnormalities which supported by the histopathological alteration in testis. These results were in agreement with Al-Fartosi. [65] These effects may be according to the changes in the expression of various receptors associated with cyclic guanosine monophosphate (cGMP) or in the responsiveness of these receptors in the brain, and then this will caused failure in spermatogenesis and damage in tissue of testis. [66]

CONCLUSION

The present results confirm that the *M. oleifera* leaves ingestion produce positive effects on fertility in adult New Zealand rabbit bucks. It also lends support to the claims for traditional usage of *M. oleifera* as a sexual function enhancing medicine. This may also point to the fact that the *Moringa oleifera* leaves extract are relatively safe for use nutritionally and medicinally. Thus, this study may prove to be an effective and safe alternative remedy in sexual disorders.

Table 1: Effect of *Moringa oleifera* and Sildenafil citrate on body weight of rabbit bucks.

Groups	Rabbit bucks body weights (g)			
	Week 1	Week2	Week3	Week4
Control	2641.66+150.23 ^a	2665.00+141.46 ^a	2803.33+89.91 ^a	2555.00+33.54 ^a
Sildenafil citrate	2665.00+230.31 ^a	2650.00+201.24 ^a	2540.00+160.99 ^{ab}	2260.00+62.60 ^{ab}
MOE 200mg/kg	2486.66+90.57 ^a	2493.33+101.57 ^a	2496.66+141.17 ^{ab}	2556.66+148.98 ^a
MOE 400mg/kg	2416.66+59.19 ^a	2393.33+65.45 ^a	2333.33+66.81 ^b	2193.33+108.52 ^b

Data are expressed as the mean \pm standard deviation (SD). Different superscripts within the same column designate significant differences ($p \leq 0.05$). MOE: Moringa oleifera Extract.

Table 2: Effect of *Moringa oleifera* aqueous extracts on Thyroid hormones and testosterone levels in rabbit bucks.

Treatment	T3 (pg/dl)	T4 (ng/dl)	TSH (μ U/ml)	Testosterone (ng/dl)
Control	3.067 \pm 0.067 ^c	1.100 \pm 0.057 ^b	0.009 \pm 0.0003 ^a	750 \pm 3.464 ^d
Sildenafil citrate	4.21 \pm 0.288 ^b	1.250 \pm 0.086 ^b	0.0093 \pm 0.0003 ^a	1034 \pm 3.197 ^c
MOE 200mg/kg	5.346 \pm 0.144 ^a	1.500 \pm 0.144 ^a	0.0100 \pm 0.0003 ^a	1053 \pm 2.309 ^b
MOE 400mg/kg	5.900 \pm 0.346 ^a	1.700 \pm 0.153 ^a	0.0098 \pm 0.0001 ^a	1193 \pm 1.732 ^a

Data are expressed as the mean \pm standard deviation (SD). Different superscripts within the same column designate significant differences ($p \leq 0.05$). MOE: *Moringa oleifera* Extract

Table 3: Effect of *Moringa oleifera* aqueous extracts as safety profile agent on liver and kidney functions in rabbits bucks

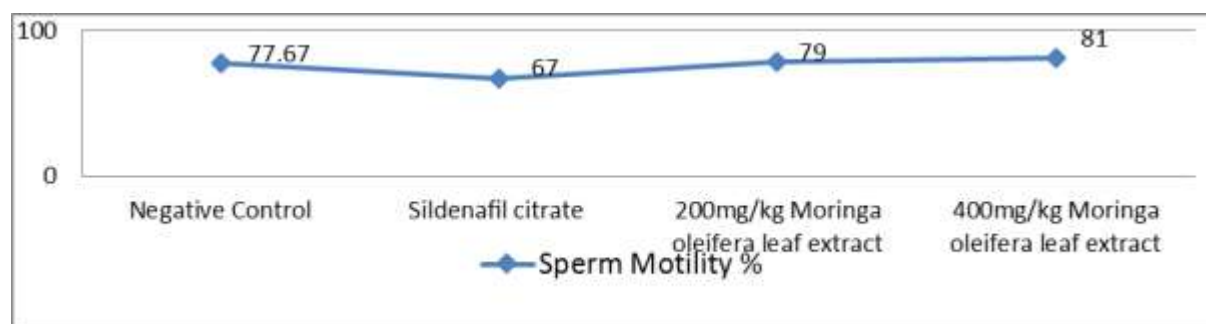
Group	Total protein	Glutamic - oxalacetic Transaminase IU/L	Glutamic pyruvic Transaminase IU/L	Creatinine mg/dL	Urea mg/Dl	Uric acid mg/dL
Control	5.03 \pm 0.09 ^a	134.33 \pm 0.38 ^c	75.53 \pm 2.28 ^c	1.60 \pm 0.06 ^a	3.88 \pm 0.18 ^b	6.69 \pm 0.74 ^a
Sildenafil citrate	4.70 \pm 0.21 ^a	166.43 \pm 0.30 ^a	105.00 \pm 0.35 ^b	1.50 \pm 0.06 ^a	4.900 \pm 0.09 ^a	7.29 \pm 0.58 ^a
MOE 200mg/kg	4.77 \pm 0.19 ^a	147.10 \pm 1.65 ^b	75.47 \pm 0.49 ^c	1.42 \pm 0.09 ^a	4.48 \pm 0.11 ^{ab}	7.04 \pm 0.16 ^a
MOE 400mg/kg	4.70 \pm 0.10 ^a	111.166 \pm 1.79 ^d	78.00 \pm 1.16 ^c	1.50 \pm 0.06 ^a	3.67 \pm 0.17 ^b	4.28 \pm 0.11 ^c

Data are expressed as the mean \pm standard deviation (SD). Different superscripts within the same column designate significant differences ($p \leq 0.05$). MOE: *Moringa oleifera* Extract.

Table 4: Effect of *Moringa oleifera* aqueous extracts as safety profile agent on lipid profile functions in rabbits bucks

Treatment	Total cholesterol (mg/dl)	HDL (mg/dl)	LDL (mg/dl)	Triglyceride (mg/dl)	Total lipid (mg/dl)
Control	145.42 \pm 1.21 ^b	78.84 \pm 1.92 ^b	83.83 \pm 4.53 ^b	343.60 \pm 19.60 ^b	2779.57 \pm 8.55 ^a
Sildenafil citrate	213.87 \pm 5.64 ^a	63.46 \pm 1.76 ^c	100.52 \pm 0.49 ^a	578.90 \pm 2.83 ^a	2666.43 \pm 88.09 ^a
MOE 200mg/kg	130.90 \pm 1.43 ^c	72.90 \pm 3.31 ^b	66.06 \pm 1.08 ^c	320.27 \pm 4.18 ^b	1944.70 \pm 51.47 ^b
MOE 400mg/kg	131.60 \pm 1.97 ^c	110.02 \pm 0.53 ^a	57.95 \pm 1.02 ^d	207.33 \pm 1.20 ^c	1970.57 \pm 73.35 ^b

Data are expressed as the mean \pm standard deviation (SD). Different superscripts within the same column designate significant differences ($p \leq 0.05$). MOE: *Moringa oleifera* Extract; HDL: high-density lipoprotein; LDL: low-density lipoprotein.

**Fig 1: Effect of *Moringa oleifera* leaves aqueous extract and Sildenafil citrate on sperm motility of rabbit bucks.**

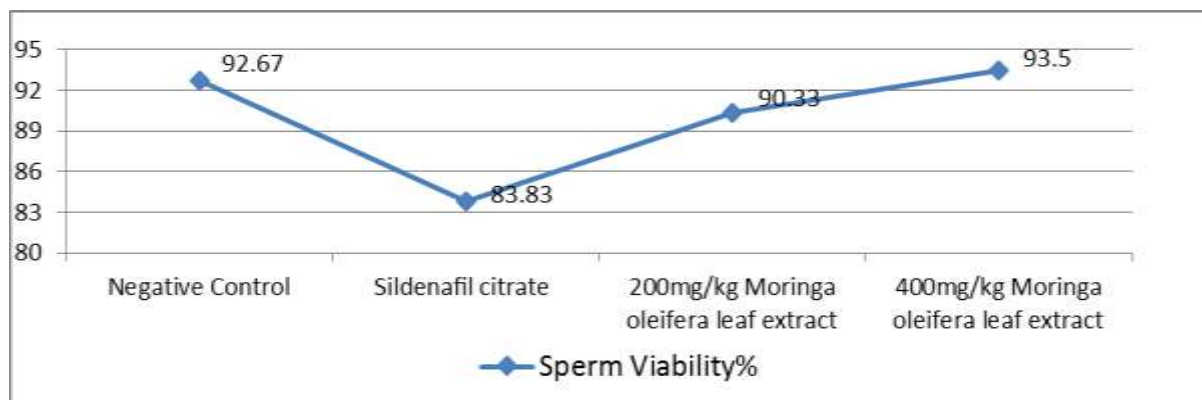


Fig 2: Effect of Moringa oleifera leaves aqueous extract and Sildenafil citrate on sperm viability of rabbit bucks.

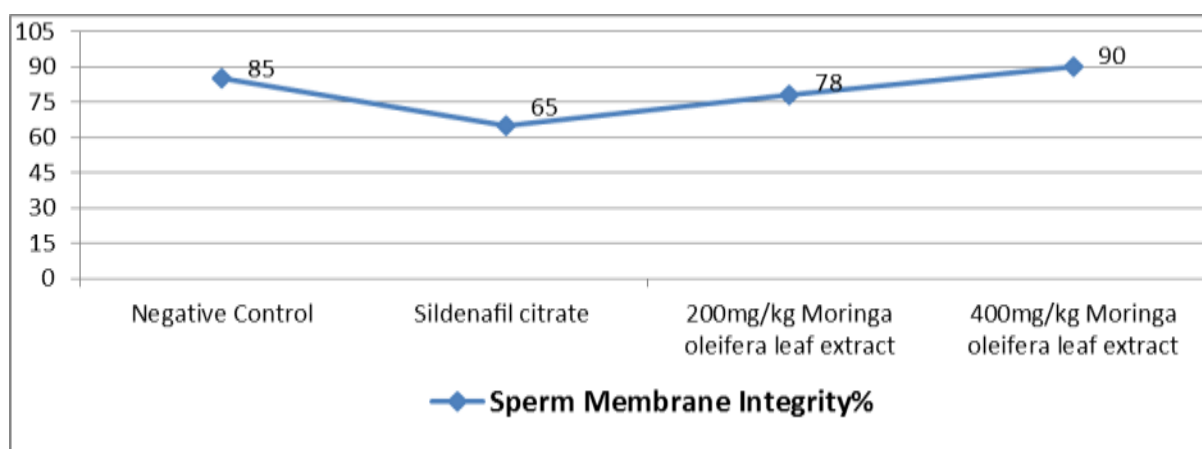


Fig 3: Effect of Moringa oleifera leaves aqueous extract and Sildenafil citrate on sperm membrane integrity of rabbit bucks.

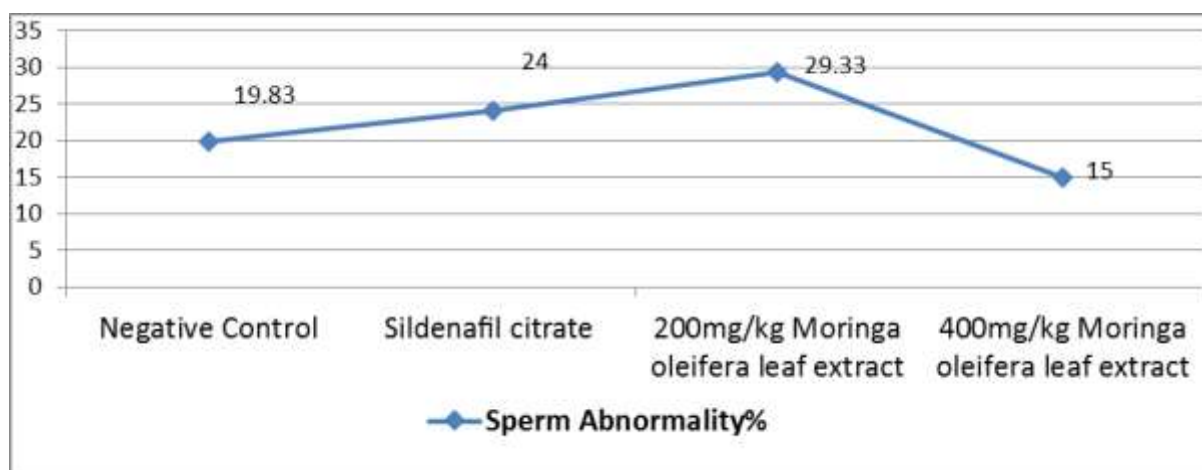


Fig 4: Effect of Moringa oleifera leaves aqueous extract and Sildenafil citrate on sperm morphological abnormalities of rabbit bucks.

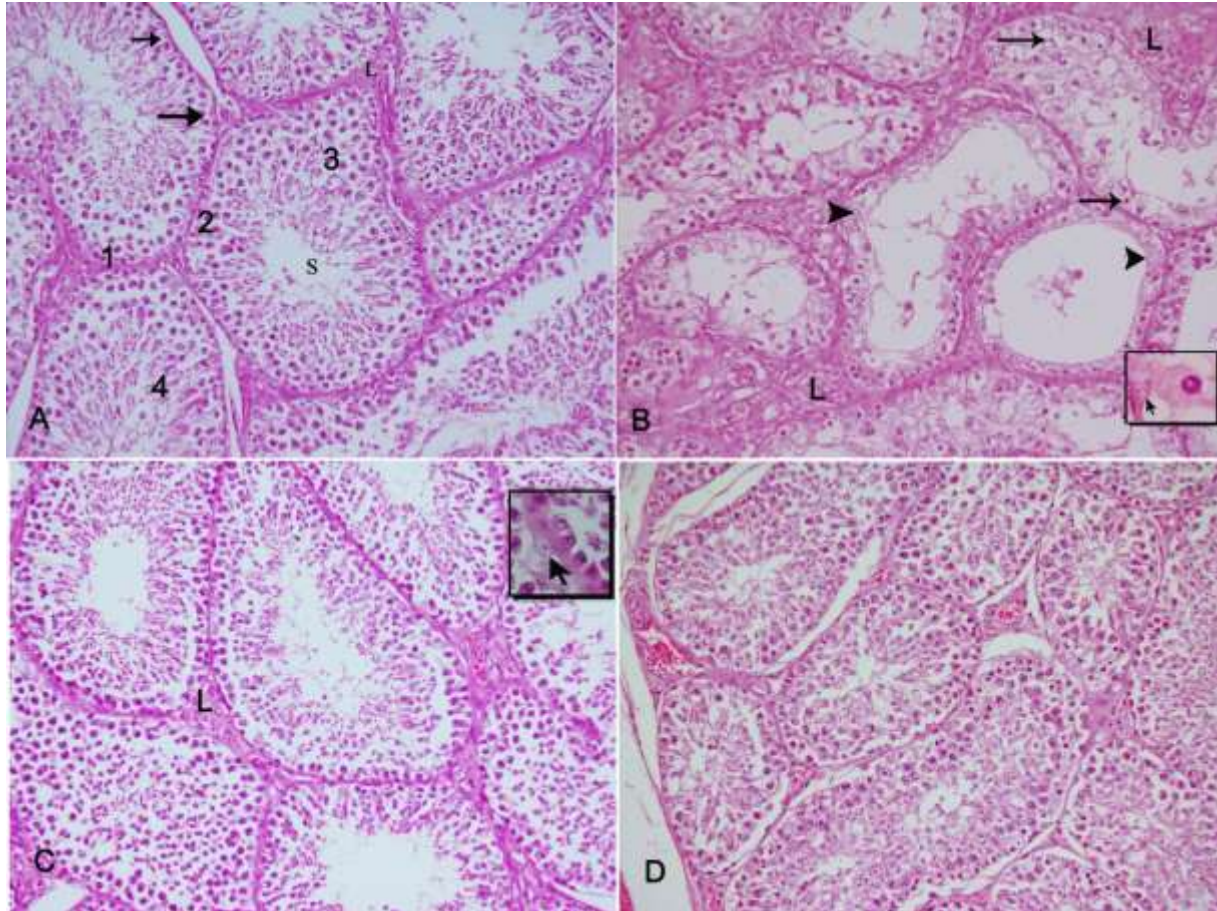


Fig 5: Sections in rabbit bucks testicular tissues (A): normal structure of seminiferous tubule (s), the germinal epithelium cells at different stages of spermatogenesis cells, 1: spermatogonia ,2: spermatocyte, 3: spermatid ,4: spermatozoa , sertoli cells (arrow) and Leydig cells (L). (B): Sildenafil citrate treated animal showing severe erosion and degeneration of the germinal epithelial layer of the seminiferous tubules showing spermatocytes pyknosis (arrow) ,degeneration (arrow head), consequent few or absence of spermatozoa cells in the lumen of the tubules. Thickening in interstitial areas, increase in leydig cells numbers (L), { **Inset** } sertoli cell atrophied (arrow) and pyknotic spermatocyt, (C): Rabbit bucks administered 200mg/kg aqueous *Moringa oleifera* leaves extract showing improvement in spermatogenesis, seminiferous tubule with, spermatogonia, spermatocytes, spermatids more regularly arranged and numerous, as well as spermatozoa. { **Inset** } : illustrate sertoli cell and spermatogonia cells appeared almost normal than those of control and (D): Rabbit bucks treated with 400mg/kg aqueous leaves extract of Moringa showing hyperactivity of gremlinal epithelium cells, increases in numbers of cells at all stages of spermatogenesis, as well as, increase the population of the sperm cells in the lumen of the seminiferous tubules (H &E 200x)

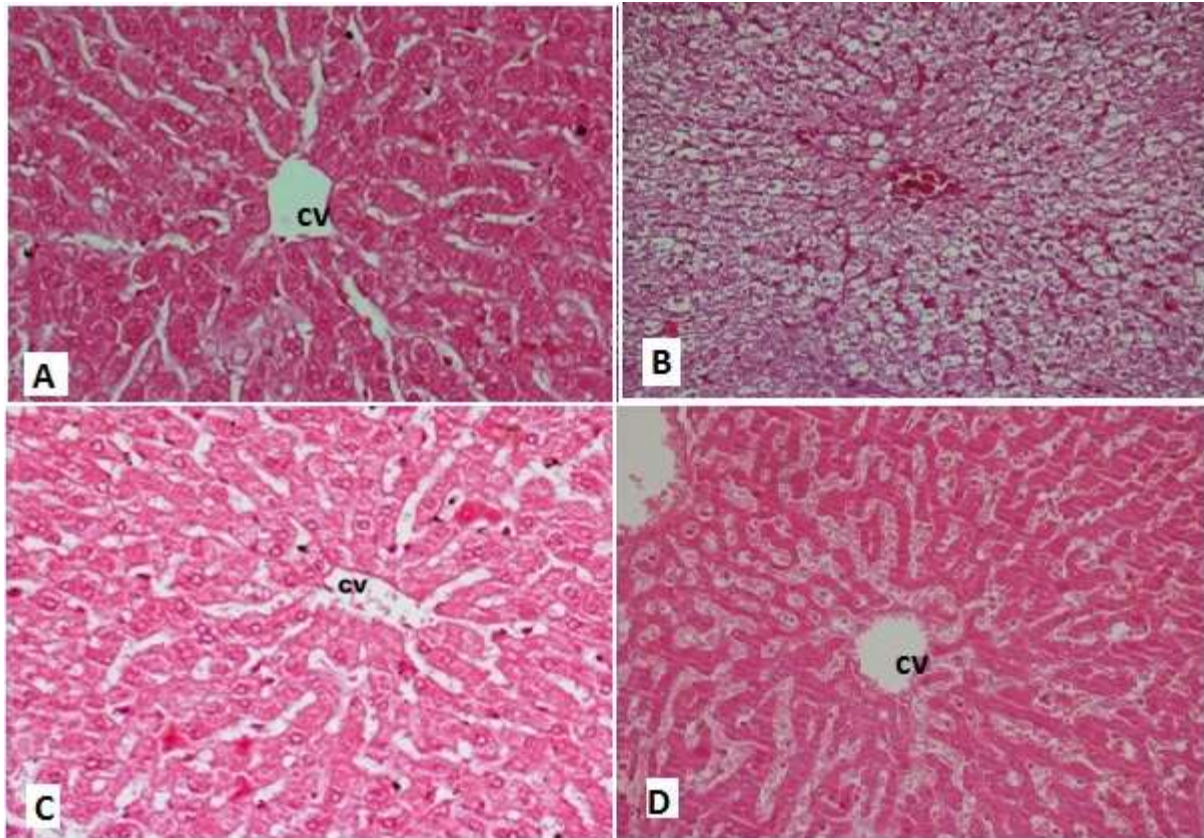


Figure 6: Section of rabbit bucks liver tissue (A): Normal structure of hepatic lobule (CV), cords of liver cells extended from central vein to the periphery of the lobule, (B): Sildenafil citrate treated animal showed severe damaged of hepatocytes ,congestion of central vaine and sinusoids ,vacuolar and fatty degeneration of hepatic cells, (C): *Moringa oleifera* leaves extract 200mg treated animal showing normal structure of hepatic tissue ,moderate dilation of blood sinusoids and hypertrophied of kupffer cells and (D): *Moringa oleifera* leaves extract 400mg treated animal showing structure of liver tissue nearly normal except dilation of central vein and sinusoids which appeared field with blood (H &E 200x).

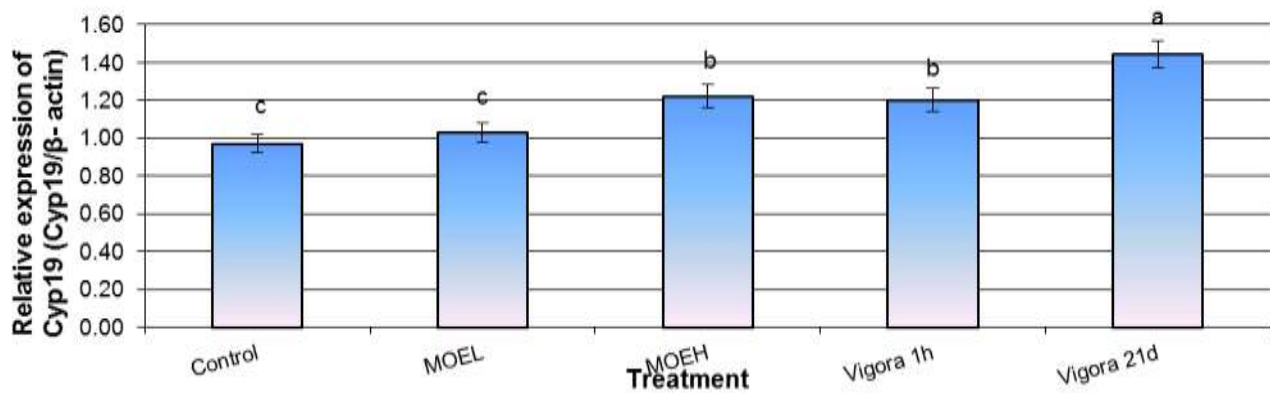


Fig 7: The relative expression of Cyp 19 gene in testis of male rabbits after exposure to low (L) and high (H) doses of *Moringa oleifera* extract (MOE, 200 and 400 mg/kg b.w) and/or sildenafil citrate (Viagra, 5 mg/kg, b.w). Mean values in the same column with different superscript differ significantly ($P \leq 0.05$).

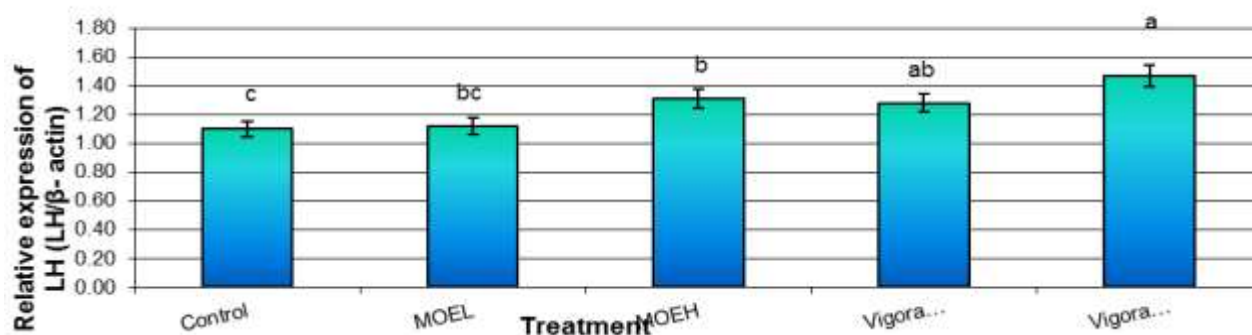


Fig 8: The relative expression of LH gene in brain tissues of male rabbits after exposure to low (L) and high (H) doses of *Moringa oleifera* extract (MOE, 200 and 400 mg/kg b.w) and/or sildenafil citrate (Vigora, 5 mg/kg, b.w). Mean values in the same column with different superscript differ significantly ($P \leq 0.05$).

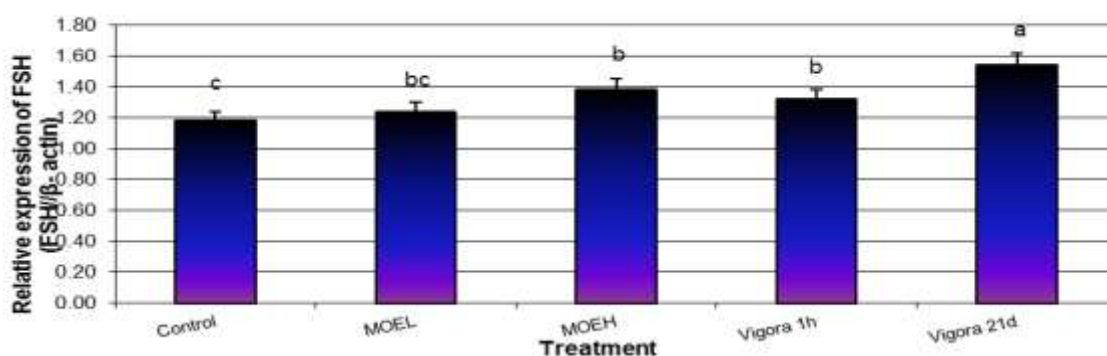


Fig 9: The relative expression of FSH gene in brain tissues of male rabbits after exposure to low (L) and high (H) doses of *Moringa oleifera* extract (MOE, 200 and 400 mg/kg b.w) and/or sildenafil citrate (Viagra, 5 mg/kg, b.w). Mean values in the same column with different superscript differ significantly ($P \leq 0.05$).

REFERENCES

- Ogbe FM, Dania OLE, Marilyn U. Nigeria Scient Res Essay, 2009; 4 (3): 120-130.
- Anthony BO, Oladipupo AL, Adedoyin KL, Tajuddin IA. The Sci World J, 2006; 6: 2140-2146.
- Sharma JD, Sharma L, Yadav P. Asian J Exp Sci, 2007; 21(1): 145-150.
- Vasudeva N, Sharma SK. Oxford Journals, 2007; 5 (1): 91-94.
- Singh A, Singh SK. Contraception, 2009; 71-79.
- Bhatia DK, Sharma AK, Pathania PC, Khanduri NC. Biol Forum- An Int J, 2010; 2(2): 88-93(2010).
- Yakubu MT, Akanji MA, Oladiji AT. Phcog Rev, 2007; 1(1):49-52
- Sumalatha K, Saravana KA, Mohana LS. Int J Pharm Ther, 2010; 1: 10-18.
- Farooq F, Rai M, Tiwari A, Khan A, Farooq S. J Med Plants Res, 2010; 6 (27): 4368-4374.
- Ufele AN, Ebenebe CI, Igwe II, Mogbo TC, Akunne EC, Aziagba BO. The Bioscientist, 2013; 1(1):106-108.
- Bennett RN, Mellon FA, Foidl N, Pratt JH, Dupont MS, Perkins L, Kroon PA. J Agric Food Chem, 2003; 51(12): 3546-3553.
- Mori S, Cameldi I, Pardini A. Associazione Scienze Agrarie Tropicali, 2009; 1: 1-2.
- Ashfaq M, Basra S, Ashfaq U. World Environment Day, 2011; 41-54.
- Tesfay S, Bertling I, Odindo A, Workneh T, Mathaba N. African J Agri Res, 2011; 6(22): 5123-5132.
- Aslam MF, Anwar R, Nadeem U, Rashid TG, Kazi A, Nadeem M. Asian J Plant Sci, 2005; 4:417-21.
- Ayssiwe SB, Zamenou JC, Issa Y, Hane MB, Dieng A, Chrysostome CAAM, Houinato MR, Hornick JL, Missouhou A. Pak J Nutr, 2011; 10: 707-717.
- Mutayoba SK, Dierenfeld E, Mercedes VA, Frances Y, Knight CD. Int J Poult Sci, 2011; 10: 350-357.
- Monera TG, Wolfe AR, Maponga CC, et al. J Infect Dev Ctries, 2008; 2(5):379-383.
- Prabsattroo T, Wattanathorn J, Iamsa-ard S, et al. Am J Neurosci, 2012; 3(1):17-24.

20. Purvis K, Christiansen E. Int J Androl, 2008; 16(1): 1-13.
21. Gamache PH, Acworth IN. Proc Soc Exp Biol Med, 1998; 217: 274-280.
22. Tietz, NW. Clinical guide to laboratory tests. 3rd ed. Philadelphia: W B Saunders, Co., 1995; p.405
23. Demers LM, Spencer CA. Laboratory medicine practice guidelines. Washington DC: National Academy of Clinical Biochemistry, 2002.
24. Fossati P, Prencipe L, Berti G. Clin Chem, 1980; 26:227–231.
25. Patton C J, Crouch SR. Anal Chem, 1977; 49 (3):464–469
26. Bartels H, Böhmer M, Heierli C. Clin Chim Acta, 1972; 37:193-197.
27. Stein EA, Adolph R, Rice V, Glueck CJ, Spitz, BH. Clin Cardiol, 1986; 9(3):115-119
28. Friedewald WT, Levy RI, Fredrickson DS. Clin Chem, 1972; 18(6):499-502.
29. Wahelfed AW. Method of Enzymatic Analysis. New York, 1974; 5:1831-1835
30. Zollner N, Kirsch K. J Exp Med, 1962; 135: 545-550.
31. Reitman A, Frankel S. Am J Clin Path, 1957; 28:56.
32. Bradford MM. Analytical Biochemistry, 1976; 72: 248-254.
33. International Rabbit Reproduction Group (IRRG). World Rabbit Sci, 2005; 13: 71 – 91.
34. Seleem TST. In Proc: The 4th Inter. Con. on Rabbit Prod. In Hot Clim, Sharm El-Sheikh, Egypt, 2005;161-168.
35. Bakst MR, Cecil HC. The Poult Sci Assoc ,2005; Inc., Savoy Illinois.
36. Moce E, Vicente JS, Lavara F, Lavara R, Marco-Jimenez F. Reprod in Domestic Animal, 2004; 39, 4, 265.
37. Khalil W K B, Abdu F. Arch Med Sci, 2015; 11(3):660-9.
38. SAS . SAS Institute Inc., 1982; Cary, NC.
39. Adedapo AA, Mogbojuri OM, Emikpe BO. J Med plants Res, 2009; 3(8):586-591.
40. Cajuday AL, Pocsidio LG. J Med Plant Res, 2010; 4 (12):115-1121.
41. Stohs SJ, Hartman MJ. Phytother Res, 2015; 29: 796–804 (2015)
42. Watcho P, Donfack MM, Zelefac F, Nguenefack TB, Wansi S, Ngoula F, Kamanyi A. Afr J Trad CAM, 2005; 2(3): 302-311.
43. Amini A , Kamkar F. Iranian J Sci Technol Trans, 2005; 29: 123-133.
44. Tabassum W, Kullu AR, Sinha MP. The Bioscan, 2013; 8(2): 665-669.
45. Huang YH, Tsai MM, Lin KH. Chang Gung Med J, 2008; 31: 325-334.
46. Singh R, Hamada AJ, Agarwal A. The Open Repro Sci J, 2011; 3:98-104
47. Watcho P, Kamtchouing P, Sokeng SD, Moundipa PF, Tantchou J, Essame JL. Asian J Androl, 2004; 6: 269-72.
48. D’cruz M. Asian J Androl, 2005; 7(4): 363-368.
49. Abu AH, Ahemen T, Ikpechukwu P . Agrosearch, 2013; 13 (1): 49 - 56.
50. Oyeyemi MO, Olukole SG, Esan O. Int J Morphol, 2008; 26(1):121-126.
51. Zade SV, Dabhadkar KD, Thakare GV, Pare RS . Biological Forum – An International J, 2013; 5(1): 129-140.
52. Kujo S . Curr Med Chem, 2004 ;11: 1041-1064.
53. Shukla VN, Khanuja SPS. J Med Aromatic Plant Sci, 2004; 26: 64- 96.
54. Gauthaman K, Adaikan PG. Phytomedicine, 2008; 15 (1): 44- 54.
55. Padashetty, SA, Mishra SH. Pharmaceutical Biol, 2007; 45(7): 580-586.
56. Mehta LK, Balaraman R, Amin AH, Bafna PA, Gulati OD. J Ethnopharmacol, 2003; 86: 191–195.
57. Diekman MJ, Anghelescu N, Endert E, Bakker O, Wiersinga WM. J Clin Endocrinol Metab, 2000; 85: 1857-1862.
58. Luqman S, Srivastava S, Kumar R, Maurya AK, Chanda D. Evidence-Based Compl Altern Med, 2012; 2012: 519084.
59. Ahemen T, Abu AH, Iorgilim LK. Arch Appl Sci Res, 2013; 5 (2):172-176.
60. Akudu, L S, Ezejindu DN, Nnama TN, Ezejindu CN. Int J Res, 2014; 1(10): 793-800.
61. Isitua CC, Ibeh IN. J Clinic Toxicol, 2013; 12:2-4.
62. Saalu LC, Osinubi AA, Akinbami AA, Yama OE, Oyewopo AO, Enaibe BU. Int J Appl Res Natu Prod, 2011 ; 4(2):32-45.
63. Zhao E, Mu Q. Scientia Pharmaceutica, 2011; 79(1):1–20.
64. Gopi R, Varma K. Asian J Pharma Tech Innov, 2015; 3 (10); 115-230.
65. Al-Fartosi KG. Bas J Vet Res, 2009; 8(2): 91-103.
66. Ali ST, Rakkah NI. Pak J Pharm Sci, 2007; 20(1):36-42.